

**PATIENT**

Sophie Twyer

**SPECIES**

Canine

**BREED**

Lagotto Romagnola

**SEX**

FS

**AGE**

11 years

**WEIGHT**

17.4 kg

**INTERPRETED BY**

Remo Lobetti, BVSc,  
MMedVet (Med), PhD,  
Dipl. ECVIM

**IMAGING PERFORMED BY**

Dr Donna Markland,  
DVM

**HOSPITAL NAME**

Duncan Animal Hospital

**REFERRING VET**

**INVOICE**

302758

**DATE**

8/24/22

**PRESENTING CLINICAL SIGNS**

History: Chronic intermittent diarrhea, recent weight loss and vomiting.

Physical Examination: Normal.

Urinalysis: N/A.

CBC: Monocytosis.

Serum Biochemistry: Hypoproteinemia.

Radiographic Findings: N/A.

**ULTRASONOGRAPHIC EXAMINATION OF THE ABDOMEN**

**Urinary System**

Full urinary bladder with a normal appearance and thickness of the wall. Normal anechoic urine with no sediment or uroliths evident.

Normal trigone area, proximal urethra, and iliac blood vessels.

Normal iliac lymph nodes. Ureters not visualized.

Normal renal size (left 6.3 cm, right 6.1 cm), echogenic appearance, cortico-medullary differentiation, capsule, and pelvis.

**Reproductive System**

N/A.

**Adrenal Glands**

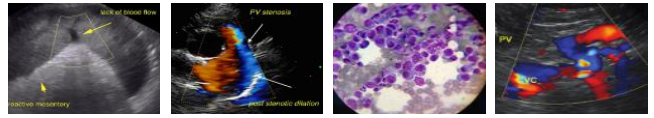
Normal shape, echogenic appearance, size, and position. Left 1.61 x 0.49/0.37 cm, right 0.61 cm.

**Spleen**

Normal size and echogenic appearance. Smooth homogenous parenchyma, smooth curvilinear capsule, and normal vasculature. No evidence of inflammatory, neoplastic, infarction, or infiltrative changes noted.

**Liver**

Normal size, echogenic appearance, portal markings, and regular curvilinear capsule. No nodules or masses evident. Full gall bladder containing moderate amount of hyperechogenic sediment. Normal thickness and appearance of the gall bladder wall. Normal bile duct.



**PATIENT**

Sophie Twyer

**SPECIES**

Canine

**BREED**

Lagotto Romagnola

**SEX**

FS

**AGE**

11 years

**WEIGHT**

17.4 kg

**INTERPRETED BY**

Remo Lobetti, BVSc,  
MMedVet (Med), PhD,  
Dipl. ECVIM

**IMAGING PERFORMED BY**

Dr Donna Markland,  
DVM

**HOSPITAL NAME**

Duncan Animal Hospital

**REFERRING VET**

**INVOICE**

302758

**DATE**

8/24/22

***Gastrointestinal***

Normal appearance of the stomach, ileo-cecal junction, and colon with no loss of layering, normal wall thickness and peristalsis, and no distension of the lumen. Normal thickness of the duodenum and small intestine with a prominent hypoechoic appearance of the submucosal layer but with no loss of layering or distension of the lumen.

***Pancreas***

Normal size and echogenic appearance. Regular capsule. Normal echogenic appearance of the mesentery and fat surrounding the pancreas.

***Free Abdomen***

Prominent mesenteric lymph nodes with normal shape and echogenic appearance.  
No ascites.

**ULTRASONOGRAPHIC FINDINGS**

Primary findings:

- Enteropathy.
- Lymphadenomegaly.
- Mesenteric inflammation.

Secondary findings:

- Gall bladder sediment.

**INTERPRETATION OF THE FINDINGS & FURTHER RECOMMENDATIONS**

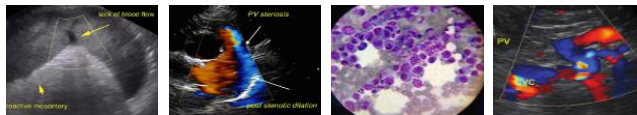
Etiologies for the enteropathy would be parasitic enteritis, inflammatory bowel disease, primary lymphangectasia, and dietary hypersensitivity.

Both the lymphadenomegaly and mesenteric inflammation can be ascribed as reactive secondary to the enteropathy.

Although the gall bladder sediment may be an incidental finding, monitoring for development of a mucocele would be recommended.

Further assessment would fecal analysis, cobalamin assay, and endoscopy of the upper GI tract with biopsies.

Specific therapy would be dependent on an etiological diagnosis. Symptomatic therapy would be novel protein/hypoallergenic diet, course of metronidazole and/or fenbendazole, cobalamin supplementation, and possible prednisolone.



**PATIENT**

Sophie Twyer

**SPECIES**

Canine

**BREED**

Lagotto Romagnola

**SEX**

FS

**AGE**

11 years

**WEIGHT**

17.4 kg

**INTERPRETED BY**

Remo Lobetti, BVSc,  
MMedVet (Med), PhD,  
Dipl. ECVIM

**IMAGING PERFORMED BY**

Dr Donna Markland,  
DVM

**HOSPITAL NAME**

Duncan Animal Hospital

**REFERRING VET**

**INVOICE**

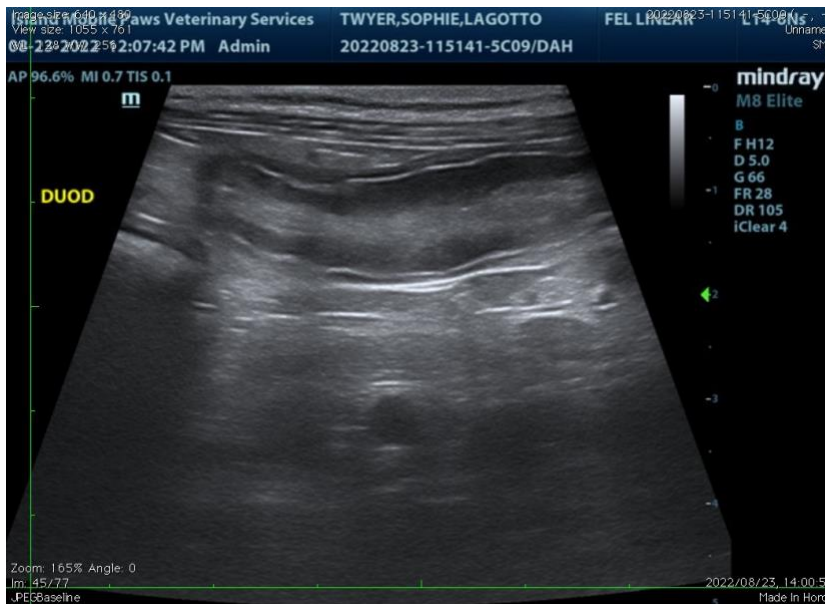
302758

**DATE**

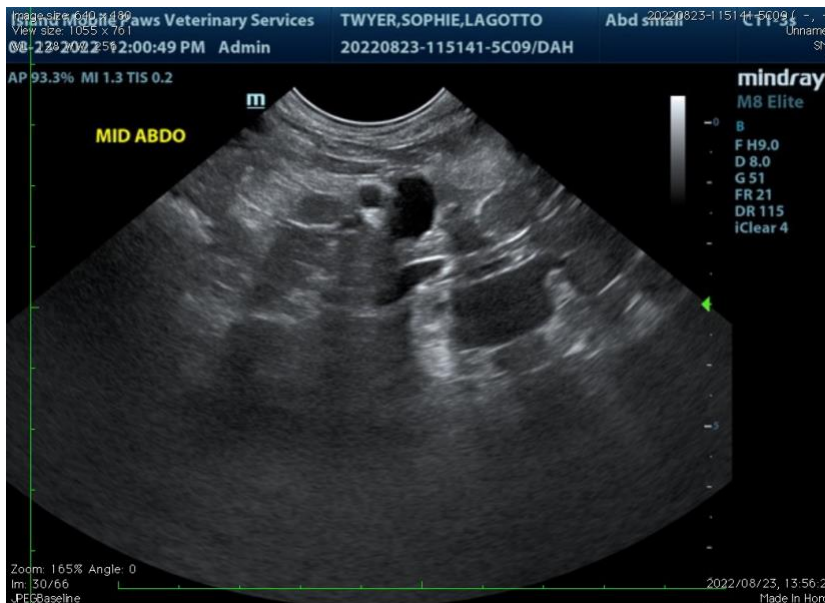8/24/22

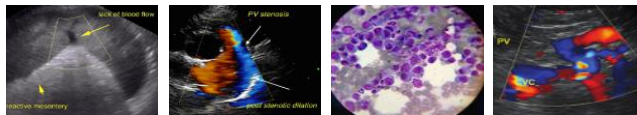
**IMAGES**

**Duodenum**



**Lymph nodes**





**PATIENT**

Sophie Twyer

**SPECIES**

Canine

**BREED**

Lagotto Romagnola

**SEX**

FS

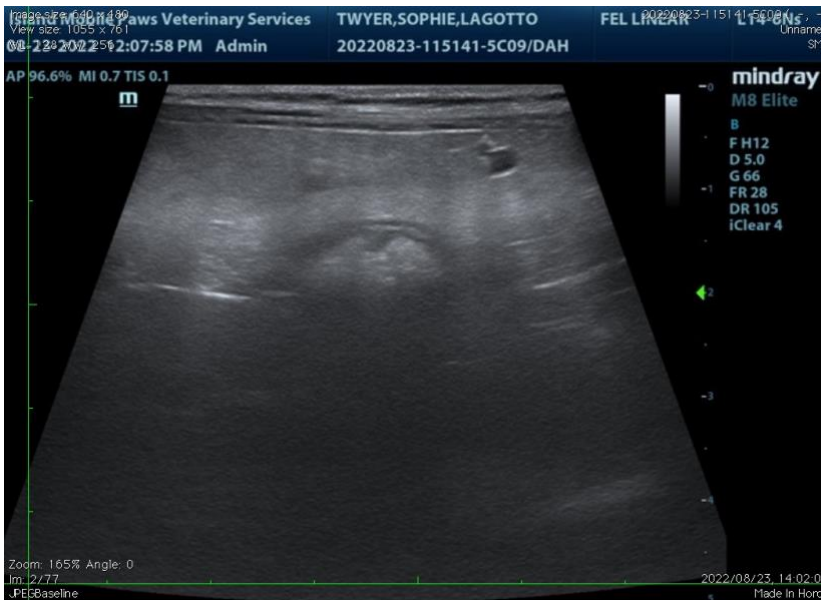
**AGE**

11 years

**WEIGHT**

17.4 kg

**Mesentery**



**INTERPRETED BY**

Remo Lobetti, BVSc,  
MMedVet (Med), PhD,  
Dipl. ECVIM

**The information and recommendations provided are based on the images presented by the referring veterinarian. No evaluation can be communicated regarding pathology that was not visible in the image/video clips provided.**

Thank you for this referral. If the clinical or image interpretation does not parallel your findings or if I can be of any further assistance please contact me.

**Remo Lobetti, BVSc, MMedVet (Med), PhD, Dipl. ECVIM (Internal Medicine)**  
rlobetti@mweb.co.za

**IMAGING PERFORMED BY**

Dr Donna Markland,  
DVM

**HOSPITAL NAME**

Duncan Animal Hospital

**REFERRING VET**

**INVOICE**

302758

**DATE**

8/24/22